

Study of Dexmedetomidine as an Adjuvant to Local Anesthetics in Peribulbar Block for Cataract Surgery

Kakhandki Srinivas¹, Mohammed Yahya², Rajashree Reddy³, Tejashwini R. Kolekar⁴

¹Associate Professor ²Assistant Professor ³Junior Resident, Department of Anaesthesia, ⁴Associate Professor, Department of Ophthalmology, Mahadevappa Rampure Medical College, Kalaburagi, Karnataka 585105, India.

Abstract

Background: Many studies show that, Dexmedetomidine hastens the onset of sensory and motor block, prolongs anaesthesia and analgesia of local anesthetics in various neural blocks. Very few studies are done using Dexmedetomidine in peribulbar block. The objective of the present study was to evaluate the effect of adding Dexmedetomidine to local anesthetics in peribulbar block for patients undergoing cataract surgery. **Methods:** Forty adult patients, scheduled for cataract surgery were randomly assigned to two equal groups. Group C (Control group) received 2.5 ml each of a mixture of 2% Lidocaine with Adrenaline and 0.5% Bupivacaine plus Hylase 150 i.u., and 0.5ml saline. Group D (Dexmedetomidine group) received 2.5 ml each of a mixture of 2% lidocaine with Adrenaline and 0.5% Bupivacaine plus Hylase 150 i.u and Dexmedetomidine 25 µg in 0.5 ml saline. Onset of sensory and motor block, duration of motor block and duration of analgesia was recorded. Pain was graded using the verbal analogue scale and recorded. Hemodynamic, and sedation parameters were recorded perioperatively. **Results:** Onset of sensory (0.925±0.348 minutes) and motor block (9.5±0.827 minutes) was significantly shorter in group D compared to group C (1.225±0.334 minutes and 11.75±1.70 minutes, being onset of sensory and motor block respectively). Duration of motor block (277±85.75 minutes) and duration of analgesia (408.8±142.456 minutes) was more prolonged in group D than in group C (163.25±46.29 minutes and 171±103.41 minutes, being duration of motor block and duration of analgesia respectively). Both groups were pain free intra-operatively. Sedation score was similar in both groups. Heart rate and blood pressure were maintained around baseline in both groups. **Conclusion:** Dexmedetomidine (25µg) as an adjuvant to a mixture of Lidocaine and Bupivacaine in peribulbar block hastens the onset of sensory and motor block, prolongs the duration of motor block and analgesia, with no side effects, and is a safe and effective for cataract surgery.

Keywords: Cataract Surgery; Dexmedetomidine; Peribulbar Block.

Introduction

For ophthalmic procedures like cataract surgery, regional anaesthesia techniques such as peribulbar blocks or retrobulbar blocks are routinely employed. Majority of the patients being elderly with associated comorbid conditions, regional anaesthesia is safer than general anaesthesia as it provides better haemodynamic stability, less respiratory depression, better postoperative analgesia, less nausea and vomiting. Retrobulbar block provides rapid

anaesthesia, akinesia, control of intra ocular pressure and good postoperative analgesia but is associated with complications like globe-perforation, brainstem anaesthesia and retrobulbar haemorrhage. Peribulbar block though safe and simple technique requires large volumes of local anaesthetics, onset of akinesia is delayed, duration of block is short [1,2,3,4], to overcome this, many adjuvants like Clonidine, Hyaluronidase, Adrenaline, Sodium-bicarbonate, Neo-stigmine, Opioids are added to local anaesthetic mixtures with limited success [5,6,7,8].

Corresponding Author: Kakhandki Srinivas, Associate Professor, Department of Anaesthesiology, Mahadevappa Rampure Medical College, Kalaburagi, Karnataka 585105, India.
E-mail: kakhandkisrinivas@gmail.com

Received on 31.03.2017, Accepted on 07.04.2017

Dexmedetomidine is a centrally acting specific α -2 agonist used as sedative, pre-emptive analgesic, to maintain haemodynamic stability in laparoscopic surgery, as adjuvant to local anaesthetics in peripheral nerve blocks, brachial plexus blocks, intrathecally and epidurally [9,10]. Very few studies show its efficacy in peribulbar blocks.

The present study is undertaken to evaluate Dexmedetomidine as adjuvant in peribulbar block performed with either mixture of 0.5% Bupivacaine and 2% Lidocaine with adrenaline plus Hylase 150i.u. OR mixture of 0.5% Bupivacaine and 2% Lidocaine with adrenaline plus Hylase 150i.u and Dexmedetomidine 25 μ gs.

Materials and Methods

After obtaining local ethical committee approval and informed consent from patients, 40 American Society of Anaesthesiologist (ASA) physical status I or II, patients of either sex, aged 18 to 80 years, scheduled for elective cataract surgeries under peribulbar block were prospectively enrolled in this study. Patients with hypersensitivity to study drugs, Mobitz type II/III degree heart block, symptomatic CAD, congestive heart failure (NYHA class III-IV), uncontrolled hypertension, uncontrolled diabetes, chronic Clonidine therapy, hepatic impairment, renal impairment, drug or alcohol abuse, coagulopathy, pregnancy were excluded from the study. Details of anaesthesia technique and study protocol were explained during pre-operative visit.

Patients were not premedicated, no topical anaesthetic were used prior or during surgery. Patients were randomly and equally (20 each) assigned to two groups C (control group) and D (Dexmedetomidine group), health care personnel providing direct patient care and the subjects were blinded to the study drugs being injected, medications were prepared by the anaesthesiologist not participating in the study, except for preparing the drugs. GROUP C: received 2.5 ml each of a mixture of 0.5% Bupivacaine and 2% Lidocaine with Adrenaline plus Hylase 150 iu, and saline 0.5 ml. GROUP D: received 2.5 ml each of a mixture 0.5% Bupivacaine and 2% Lidocaine with Adrenaline plus Hylase 150 iu, and 25 μ gms Dexmedetomidine in 0.5ml saline.

Technique of block

The patient was placed in supine position. The eyelids and the surrounding areas were cleaned with

Povidone 5% solution. With the eye in primary position of gaze, local anesthetic (LA) was given transcutaneously at the infero-temporal quadrant, at the junction of the medial 2/3rd and lateral 1/3rd of the lower lid, with the needle directed towards the floor of the orbit and the bevel facing the globe, after aspiration to rule out possible entry into a blood vessel. Ocular compression was applied for a few minutes.

Following observations were noted:

A - Onset of sensor block was assessed by assessing for loss of corneal reflex.

B - Onset of motor block was assessed by onset of akinesia of extraocular muscles and orbicularis oculi.

C - The duration of motor block was assessed by the recovery of ocular and eyelid movements and duration of analgesia was assessed by the appearance of pain after the block.

D - Heart rate, blood pressure and SpO₂ were recorded at 5 mins interval for the first 20mins, thereafter every 15mins till 1hr and every hourly for next 8hrs.

E - Sedation levels were assessed by three point scoring system: 0-alert, 1-drowsy, 2-asleep, 3-comatose.

F - Quality of analgesia was assessed by Patients rated verbal analog scale, with scores ranging from 0 to 4 (Grade 0- no pain; Grade 1- mild pain; Grade 2- moderate pain; Grade 3- severe pain; and Grade 4- maximum pain). Assessment was done every 5 minutes intraoperatively and hourly postoperatively. For score more than 2, injection Diclofenac Sodium was given in both groups. Duration of pain free period after the block was noted in both groups.

G - Side effects if any were noted.

Statistical Analysis

The collected data was analysed using independent Student t test and Chi square test $p < 0.05$ was considered significant.

Observation

The mean age in group C was 59.82 \pm 8.24, years and group D was 60.22 \pm 8.23 years. There was no significant difference in the age of patients between the groups, so also were the other demographic data and duration of surgery which showed no significant difference between the two groups (Table 1). Onset of sensory blockade was shorter in group D (0.925 \pm 0.348

minutes), compared to group C (1.225±0.344 minutes) [Table 2] and is statistically significant (p<.05). Onset of motor block in group D was 9.5±0.827 minutes and in group C was 11.75±1.70 minutes [Table 2], showing highly significant shorter duration of onset time of motor blockade in group D (p<.001). Duration of motor blockade in group D was 277±85.75 minutes which

was statistically significantly prolonged (p<.001) compared to motor blocked in group C which was 163.25±46.29 minutes [Table 2]. Duration of analgesia in group D was (408.8±142.56 minutes) which is significantly longer (p<.001) when compared to duration of analgesia in group C (171.5±103.41 minutes) [Table-2]. Hemodynamic parameters were

Table 1: Demographic data and duration of surgery

Variables	Group C n = 20 (mean ±SD)	Group D n = 20 (mean ±SD)	CHI- Square Test and t-test value	p-Value and Significance
Age in Years	59.82 ± 8.24	60.22 ± 8.34	t = 0.14	p > 0.1 NS
Gender M/F	8/12	10/10	X ² =0.11	p> 0.5 NS
Weight IN KGS	47.85± 9.27	48.15 ±9.03	t =0.1011	p>0.1 NS
Duration of Surgery in Minutes	31.06 ±4.14	29.85±6.94	t =0.6595	p>0.1 NS

C-control group, D- dexmedetomidine group, n- number of patients, M-male, F-female NS- Not significant, Data were expressed as mean ± standard deviation(SD), p< 0.05 is significant (S)

Table 2: Onset and duration of sensory and motor block

Variable	GROUP C n = 20 (mean ± SD in minutes)	GROUP D n = 20 (mean ± SD in minutes)	t- Test Value	P-value and Significance
Onset of Corneal Anaesthesia	1.225±0.344	0.925±0.348	t = 2.67	p< 0.05 S
Onset of Globe Akinesia	11.75±1.70	9.5±0.827	t = 5.29	p<0.001 HS
Duration of Globe Akinesia	163.25±46.29	277±85.75	t = 5.088	p <0.001 HS
Duration of Analgesia	171.5±103.41	408.8±142.456	t =5.87	p <0.001 HS

C-control group, D- dexmedetomidine group, n- number of patients, HS- Highly significant Data were expressed as mean ± standard deviation(SD), p< 0.05 is significant (S)

GRAPH 1

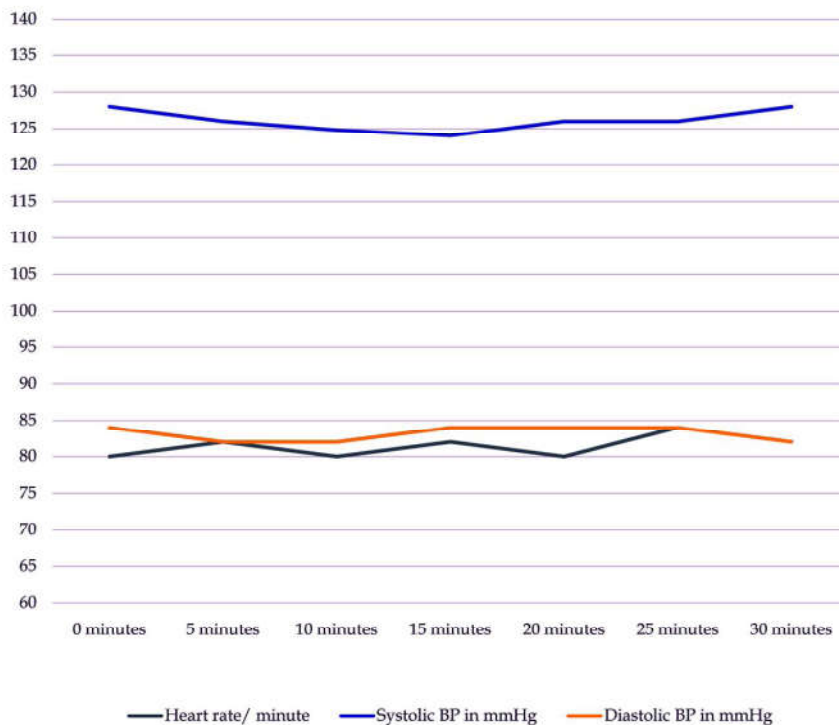


Fig. 1: Intra-operative hemodynamic parameters (mean values) in control group

Table 3: Sedation level

Sedation Level	Group C n = 20	Group D n =20
0 - ALERT	20 (100%)	20 (100%)
1 - DROWSY	0	0
2 - ASLEEP	0	0
3 - COMATOSE	0	0

C -control group , D - dexmedetomidine group , n - number of patients

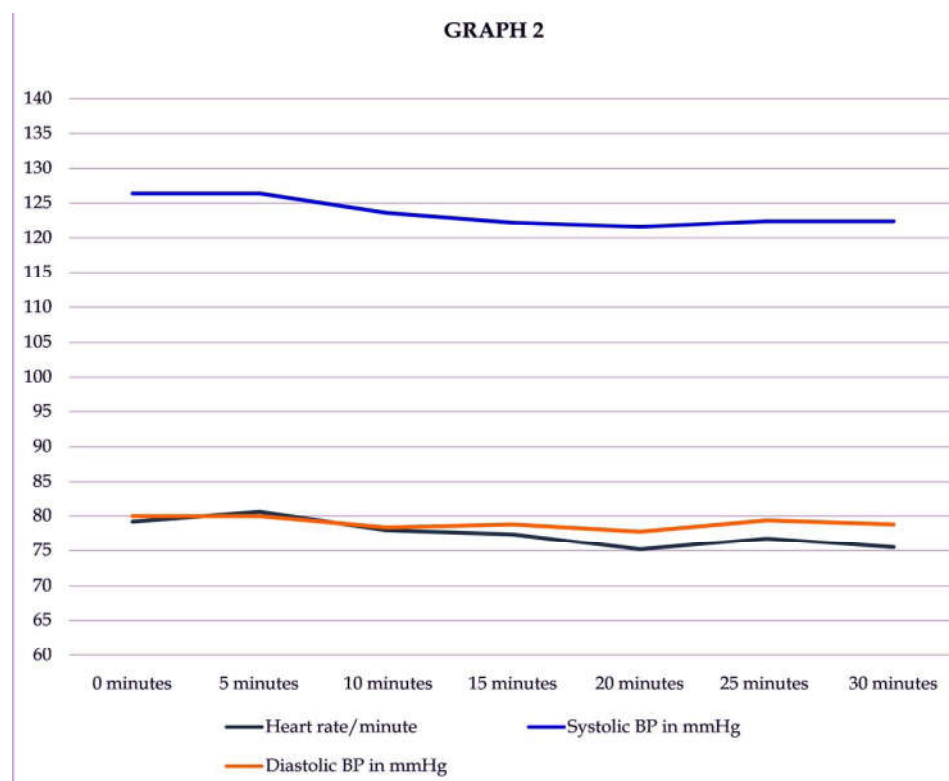


Fig. 2: Intra-operative hemodynamic parameters (mean-values) in dexmedetomidine group

maintained around baseline in both groups throughout perioperative period (Graph 1 and Graph 2). Patients were found to be alert with sedation score of- 0, in both groups (Table 3). No side effects were observed in either groups. Patients in both group did not have pain during surgery or in immediate postoperative period.

Discussion

Peribulbar block is being widely employed in ophthalmic surgeries, addition of adjuvants to local anaesthetics aims to prolong the duration of block and provide satisfactory condition for surgery. Dexmedetomidine is a selective α -2 adrenoreceptor agonist. It provides dose-dependent sedation and analgesia without respiratory depression [9], more

recently Dexmedetomidine is used as adjuvant to LA drugs in peripheral nerve block [10]. C.M. Brummet et al [11] found perineural administration of Dexmedetomidine in combination with Bupivacaine enhances sensory and motor blockade in sciatic nerve block without inducing neurotoxicity in rats. The peripheral actions of Dexmedetomidine on nerve blocks are mediated through four mechanisms, these mechanisms are: centrally mediated analgesia, α 2B adrenoreceptor mediated vasoconstrictive effects, attenuation of inflammatory response and direct action on peripheral nerve. This direct action can be explained on the basis of many studies, which propose that α 2 agonists (Clonidine, Dexmedetomidine) by enhancing activity-dependent hyperpolarization generated by the Na/K pump during repetitive stimulation, increases the threshold for initiating the action potential causing slowing or

blockage of conduction. Centrally mediated analgesia and sedation is by inhibition of substance P release in the nociceptive pathway at the level of Dorsal horn, and by the activation of α -2 adrenoreceptors in the Locus coeruleus [11,12,13,14]. Dexmedetomidine also reduces intra ocular pressure (IOP), by its direct vasoconstrictor effect on afferent blood vessels of the ciliary body resulting in reduction of aqueous humor production and also facilitates drainage of aqueous humor production by reducing sympathetically mediated vasomotor tone of the ocular drainage system [15].

Channabasappa et al [16] reported that a combination of Bupivacaine and Lidocaine with Dexmedetomidine in peribulbar anesthesia, shorten sensory and motor block onset time and extend motor and sensory block duration. Esmoğlu et al [17] reported that Dexmedetomidine as an adjuvant to levo-Bupivacaine for axillary brachial plexus block markedly prolongs the duration of the block and shortens the onset time in addition to prolongation of postoperative analgesia. Mohamed Hafez et al [18] found adding Dexmedetomidine in different doses (15 μ g, 20 μ g, 25 μ g) to a mixture of Lidocaine 2% and Bupivacaine in peribulbar block shortened sensory and motor block onset, extended the analgesia period and the motor block duration. It also significantly decreased the intraocular pressure and enabled better operating conditions. In their study, the addition of Dexmedetomidine 25 μ g to the local anesthetic mixture showed the best outcome.

We noticed that, there was a significant decrease in the onset time of sensory and motor block when using Dexmedetomidine (Group D) as adjuvant to LA in patients undergoing cataract surgery with peribulbar block (Table 2) in comparison to when using LA alone (Group C). Duration of analgesia and motor block showed a significant increase in the length of the block in Group D, in comparison with Group C (Table 2), there was no significant difference between Group D and Group C with respect to sedation (Table 4). Heart rate and blood pressure remained around baseline in both groups. The effect of Dexmedetomidine as an adjuvant to LA in patients undergoing cataract surgery with peribulbar block in the present study was similar to aforementioned study of Chennabasappa et al, however mean duration of analgesia and motor block was longer in our study probably due to use of Lidocaine with Adrenaline. The addition of Dexmedetomidine (25 μ g) to the local anesthetic mixture was found to be adequate in our group of patients with no side effects, similar to Mohammed Hafez et al.

Conclusion

Dexmedetomidine is a useful drug as an adjuvant to LA, in peribulbar anesthesia, as it shortens onset time, prolongs motor block and duration of analgesia, with no side effects.

References

1. Goerig M, Bacon D, van Zundert A. Carl Koller, cocaine, and local anesthesia: Some less known and forgotten facts. *Reg Anesth Pain Med.* 2012;37:318-24. [PubMed].
2. Davis DB, 2nd, Mandel MR. Posterior peribulbar anesthesia: An alternative to retrobulbar anesthesia. *J Cataract Refract Surg.* 1986;12:182-4. [PubMed].
3. Davis DB, 2nd, Mandel MR. Efficacy and complication rate of 16,224 consecutive peribulbar blocks. A prospective multicenter study. *J Cataract Refract Surg.* 1994;20:327-37. [PubMed].
4. Riad W, Akbar F. Ophthalmic regional blockade complication rate: A single center audit of 33,363 ophthalmic operations. *J Clin Anesth.* 2012;24:193-5. [PubMed].
5. Eldeen HM, Faheem MR, Sameer D, Shouman A. Use of clonidine in peribulbar block in patients undergoing cataract surgery. *Aust J Basic Appl Sci.* 2011;5:247-50.
6. Sarvela PJ. Comparison of regional ophthalmic anesthesia produced by pH-adjusted 0.75% and 0.5% bupivacaine and 1% and 1.5% etidocaine, all with hyaluronidase. *Anesth Analg.* 1993;77:131-4. [PubMed].
7. Zahl K, Jordan A, McGroarty J, Sorensen B, Gotta AW. pH-adjusted bupivacaine and hyaluronidase for peribulbar block. *Anesthesiology.* 1990;72:230-2. [PubMed].
8. Abdelatif AA, El Shahawy MA, Ahmed AI, Almarakbi WA, Alhashemi JA. Effects of local low-dose rocuronium on the quality of peribulbar anesthesia for cataract surgery. *Saudi J Anaesth.* 2011;5:360-4. [PMC free article] [PubMed].
9. Paris A, Tonner PH. Dexmedetomidine in anesthesia. *Curr Opin Anaesthesiol.* 2005;18:412-8. [PubMed].
10. Gandhi RR, Shah AA, Patel I. Use of dexmedetomidine along with bupivacaine for brachial plexus block. *Natl J Med Res.* 2012;2:67-69.
11. Brummett C, Norat M, Palnisano J, Lydi R. Perineural administration of Dexmedetomidine in combination with Bupivacaine enhances sensory and motor blockade in Sciatic nerve block without inducing neurotoxicity in rat. *Anesthesiology* 2008;109:502-11.
12. C.Dalle, M. Schneider, F. Clergue, C. Bretton, P. Jirounek. Inhibition of the I(h) current in isolated peripheral nerve: a novel mode of peripheral antinociception? *Muscle Nerve*, 2001;24:254-261.
13. T. Kosugi, K. Mizuta, T. Fujita, M. Nakashima, E. Kumamoto. High concentrations of dexmedetomidine inhibit compound action potential in frog sciatic nerve without α 2 adrenoreceptor activa *Br J Pharmacol*, 2010;160:1662.
14. C.M. Brummett, E.K. Hong, A.M. Janda, F.S. Amodio, R. Lydic. Perineural dexmedetomidine added to ropivacaine

- for sciatic nerve block in rats prolongs the duration of analgesia by blocking the hyper polarization activated cation current *Anesthesiology*, 2011;115:836-843.
15. Vartianinen J, MacDonald E, Urtti A, Ronhiainen H, Virtanen R. Dexmedetomidine induced ocular hypotension in rabbits with normal or elevated intraocular pressure. *Invest Ophthalmol Vis Sci*. 1992;33:2019-23. [PubMed] hypotension.
 16. Channabasappa SM, Shetty VR, Dharmappa SK, Sarma J. Efficacy and safety of dexmedetomidine as an additive to local anesthetics in peribulbar block for cataract surgery. *Anesth Essays Res*. 2013;7:39-43. [PMC free article].
 17. Esmaoglu A, Yegenoglu F, Akin A, Turk CY. Dexmedetomidine added to levobupivacaine prolongs axillary brachial plexus block. *Anesth Analg*. 2010;111:15.
 18. Mohamed Hafeza, Mona Raafat Fahimb, Mona Hossam Eldin Abdelhamida, Maha Mohamed Ismail Youssef, Abeer Samir Salem. The effect of adding dexmedetomidine to local anesthetic mixture for peribulbar block in vitreoretinal surgeries *Egyptian Journal of Anaesthesia*. 2016;32(4):573-79. [PubMed].
-